

## Arteriovenous Malformation in Crouzon Syndrome: A Case Report

R.K. Sharma, A. Kapoor

Department of Pediatrics, People's College of Medical Sciences & Research Centre, Bhopal-462037

(Received April, 2013)

(Accepted June, 2013)

### Abstract:

Crouzon syndrome, a hereditary syndrome of craniofacial dysostosis, is a triad of skull deformities, facial anomalies and exophthalmos. It accounts for approximately 4.8% of all cases of craniosynostosis with the prevalence of approximately 1 per 25,000 live births worldwide. This is a case of Crouzon syndrome with arteriovenous malformation over vertex which has not been reported so far in the literature.

**Key Words:** Craniosynostosis, Crouzon syndrome, Arteriovenous malformation.

### Introduction:

Craniosynostosis is a condition where baby is born with, or develop later on one or more fused cranial suture resulting in skull deformities and the disturbances in the normal brain development. Most of the patients are nonsyndromic but it could be associated with more than 130 different syndromes. Some of the syndromes associated with craniosynostosis are Apert syndrome, Crouzon syndrome, Pfeiffer syndrome and Saethre-Chotzen syndrome.

Crouzon syndrome was first described by a French neurologist, Octave Crouzon (Crouzon, 1912). It is a hereditary syndrome of craniofacial dysostosis which includes a triad of skull deformities, facial anomalies and exophthalmos. It is also known as dysostose cranio- faciale hereditaire or dysostosis cranio-facialis.

### Case Report:

A four and a half year old boy presented in Paediatric OPD with complaints of abnormal shape of head with bulging of eyeballs. He also complained of snoring and nasal stuffiness for last two years. He was a full term baby, delivered by normal vaginal route in hospital and cried immediately after birth. There was no history of consanguinity in parents. No other family member or sibling was affected with the same complaints. He was fully vaccinated. His development was appropriate for his age. He did not have any symptoms of raised intracranial hypertension like headache or vomiting.

On examination, his vital parameters were normal and his anthropometric measurements (Weight -10.64 kg, Height -95 cm, Head Circumference - 46.5 cm) were below 3<sup>rd</sup> percentile. His head was small and triangular in shape; he had bilateral proptosis, hypertelorism and low set ears (Fig. I). His nasal bridge was depressed and teeth were overcrowded. There was a pulsatile boggy swelling present at vertex measuring approximately 3cmX3cm. Extremities were normal and there was no syndactyly or polydactyly. His ENT examination revealed deviated nasal septum. Ophthalmology evaluation reported normal vision, telecanthus and exotropia. His dental examination showed normal dentition with no enamel-dentine hypoplasia. He had class 3 lower jaw protrusion and caries in upper incisors. His respiratory, cardiovascular and nervous systems were within normal limits.

On investigation, his haemogram was normal. X-Ray skull showed fused sutures, copper beaten appearance and class 3 lower jaw protrusion and maxillary hypoplasia (Fig. II). Computerized tomography of head also showed bilateral fused lambdoid, sagittal, coronal and metopic sutures (Fig. III). Orbits were small and eyeballs were protruded. There was a small bony defect at posterior fontanelle area. Ultrasonography with Doppler of the boggy swelling showed it to be an arteriovenous malformation (AVM) communicating through the defect in cranium (Fig. IV).

He was diagnosed as a case of Crouzon Syndrome with arteriovenous malformation. He was given medical therapy for snoring to which he responded very well. He was referred to Pedodontist for dental caries and jaw abnormality and was advised for regular follow up.

-----  
**Corresponding Author:** Dr. Anju Kapoor, Professor of Pediatrics, HIG-A/9, People's Campus, Bhanpur, Bhopla - 462037  
**Phone No.:** 09993958512  
**E-mail :** dranjukapoor@gmail.com

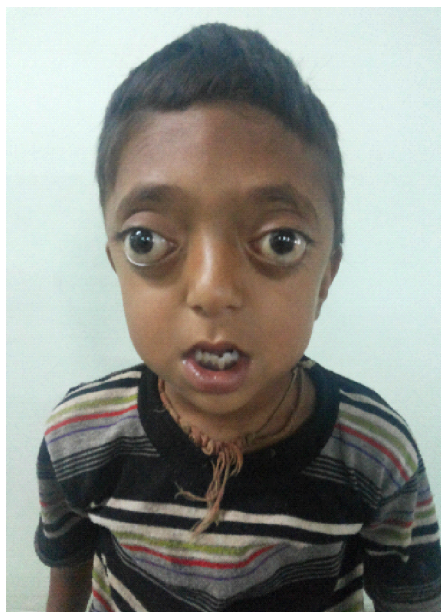

Fig. I: Photograph showing small triangular head, bilateral proptosis, low set ears and small nose.

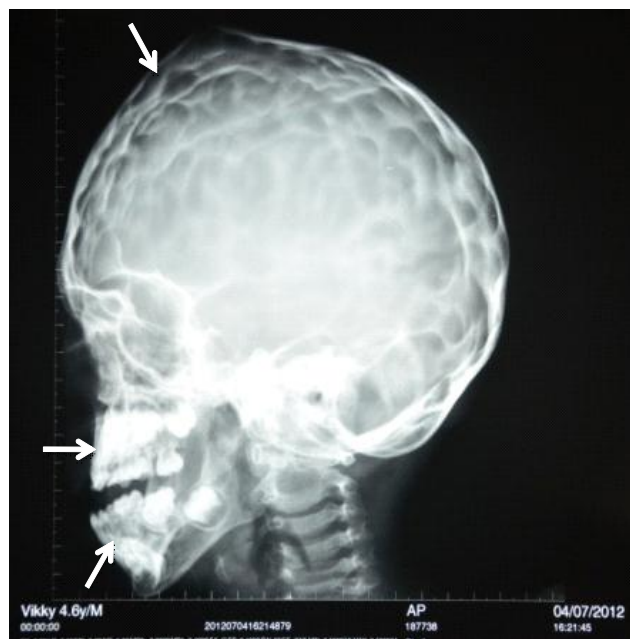

Fig. II: Photograph showing trigonocephaly, fused sutures, copper beaten appearance, small maxilla and protruded lower jaw.

## Discussion:

Craniosynostosis is a condition where baby is born with or develop fusion of one or more cranial suture in first one or two years of life. This results in skull deformities and the disturbances in the normal brain development due to the reduced volume of the intracranial space. This developmental anomaly affects 1 in 2000 children.

The six cranial sutures most commonly affected in craniosynostosis are: - Two coronal sutures,

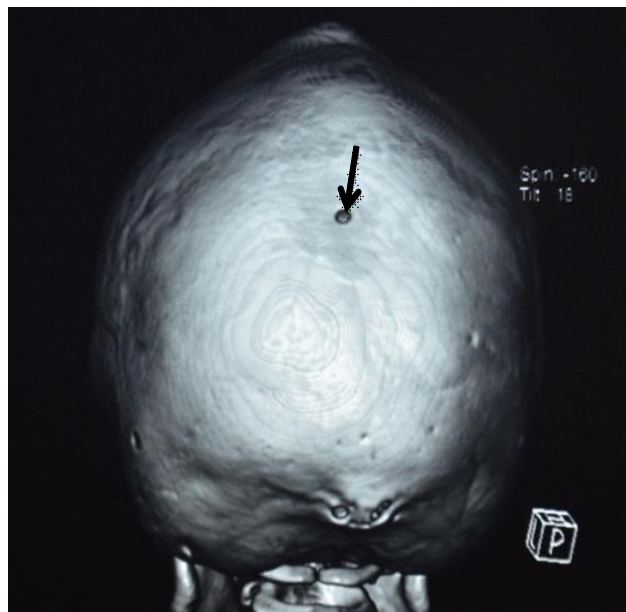


Fig. III: Photograph showing bilateral fused sutures and small defect in cranium

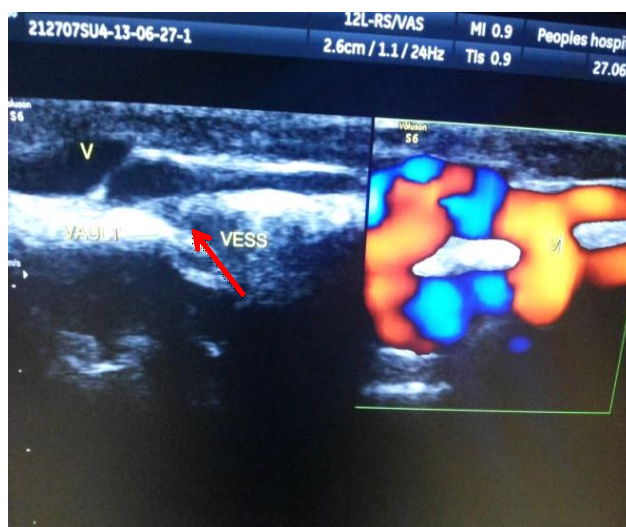


Fig. IV: USG doppler showing arteriovenous malformation seen through a bony defect on vault.

two lambdoid sutures, sagittal suture and metopic suture. Fused sutures act as a barrier to the brain growth perpendicular to it, so the compensatory growth occurs along the lines of adjacent sutures to accommodate the growing brain and this leads to abnormal shape of the head.

Major complications associated with craniosynostosis are inhibition of brain growth, hydrocephalus, raised intracranial pressure, delayed development, cognitive defect, eye problems, psychosocial and cosmetic problems.

Crouzon syndrome, first described in 1912, is an autosomal dominant genetic condition, though 25%

Table I: Clinical features of crouzon syndrome:

Head	Brachycephaly, dolichocephaly, Trigonocephaly, ridges felt at sutural lines
Brain	Hydrocephalus, raised intracranial pressure, Arnold Chiari malformation
Eyes	Exophthalmos, hypertelorism, reduced monocular visual acuity, reduced binocular visual acuity, amblyopia, optic atrophy, ametropia and hypermetropia, myopia, Manifest strabismus, keratopathy, astigmatism, anisometropia, exotropia and esotropia
Nose	Small beaked nose, Deviated nasal septum
Mid-face	Mid-face retrusion
Jaw	Relative mandibular prognathism
Ears	Low set ears, conductive hearing loss, external, middle and inner ear abnormality
Mouth	High arched palate, overcrowding of teeth, class III malocclusion
Spine	Cervical spine abnormality, fusion of cervical vertebra, scoliosis
Respiratory system	Upper airway obstruction, mouth breathing, sleep apnoea, snoring
Cutaneous	Acanthosis nigricans
Intelligence	Normal in most cases

of cases occur as a fresh mutation. The molecular analysis of craniosynostosis syndromes identifies mutations in the fibroblast growth factor receptor 2 (FGFR2) gene, located at 10q25-q26 (Reardon et al, 1994)). In patient of Crouzon syndrome with acanthosis nigricans the mutation is found in FGFR 3 gene. All the mutations were paternal in origin. Advanced paternal age was noted for the father of patient with Crouzon syndrome or Pfeiffer syndrome, compared with the fathers of control individuals. However, in the present case, the age of father was 30 years when patient was born.

Abnormalities of the head shape in Crouzon syndrome depends on the sutures involved. The most common clinical appearance is brachycephaly as it was seen in the present case. Fusion of the sutures present at base of skull leads to midfacial hypoplasia, maxillary hypoplasia, small shallow orbits and small nasal cavity which in severe cases can lead to upper airway obstruction or sleep apnoea (Table I). Snoring present in this case also suggested midfacial hypoplasia. The difference between Crouzon syndrome and other syndrome is that it is not associated with hand and feet abnormality like syndactyly or polydactyly. In the present case apart from the usual clinical features present in Crouzon syndrome, there was a large AVM present at the vertex. Even after careful literature search, we could not find a single case with this association.

### Management of Crouzon Syndrome:

Surgical intervention is mandatory to prevent complications like optic atrophy and to permit the brain to grow. Before subjecting the patient for surgery certain investigations are required for individualised treatment plan. They include CT scan head, X- Ray spine, dental X- Rays, visual and auditory evaluation. Surgery is aimed not only to improve function but to enhance the cosmetic appearance. Craniofacial surgery requires a team of plastic surgeon, neurosurgeon, maxillofacial surgeon, otolaryngologist and eye surgeon.

Imai et al (2013) showed orbital volume to be smaller in patients of Crouzon syndrome than in the Apert syndrome. Though orbit expansion following fronto-orbital advancement did not fully restore normal orbital volume, but in most cases, it was useful for alleviation of preoperative symptoms like exophthalmos, corneal erosion and conjunctivitis.

Surgical treatment varies according to the presentation of the disease and usually begins during a child's first year with fronto-orbital advancement with cranial decompression. Subsequently correction of midfacial hypoplasia needs Le Fort III osteotomy or its segmental variants, monobloc frontofacial advancement, or bipartition osteotomy (Scafati et al, 2008).

Apart from various surgeries, child may require medical support like gavage feeding, eye care to prevent keratitis, speech therapy, preventive dental care, eyeglasses to correct the vision and hearing aids. The present case had snoring during sleep which responded to medical management and did not require surgery. Filiaci et al (2013) also reported sleep disorder breathing (SDB) as 2 % for Obstructive Sleep Apnoea Syndrome and 7-8% for snoring.

Facial deformities greatly affect the social and emotional development of the affected child (Pandey et al, 2012). Family should be provided social, psychological and professional support. The adolescent years are difficult to manage with the situation. Regular meeting of parents and affected child with other families having similarly affected child will help both to cope with the problem.

A well coordinated multidisciplinary approach and timely surgery usually gives good result and a patient of Crouzon syndrome can live a normal life.

## References:

1. Crouzon LE: Dysostose cranio-faciale héréditaire. *Bulletin de la Société des Médecins des Hôpitaux de Paris*, 1912; 33: 545-555.
2. Filiaci F, Riccardi E, Ungari C, Agrillo A, Quarato D: Variation of the upper airways in pediatric patients with OSAS and retrusion of the midface. *Annali Italiani De Chirurgia*, 2013;31:84.
3. Imai K, Fujimoto T, Takahashi M, Maruyama Y, Yamaguchi K: Preoperative and postoperative orbital volume in patients with crouzon and apert syndrome. *The Journal of Craniofacial Surgery*, 2013; 24(1):191-194.
4. Pandey N, Pandey RK, Singh RK, Shah NK: Crouzon syndrome: a social stigma. *BMJ Case Reports*, 2012;10:2012.
5. Reardon W, Winter RM, Rutland P, Pulleyn LJ, Jones BM, Malcolm S: Mutations in the fibroblast growth factor receptor 2 gene cause Crouzon syndrome. *Nature Genetics*, 1994; 8(1): 98-103.
6. Scafati TC, Aliberti F, Scafati ST, Mangone GM, Scafati MT: The value of the maxillo-malar osteotomy in the treatment of Crouzon syndrome with exorbitism. *Annals of Plastic Surgery*, 2008;61(3):285-289.

**Source of Support :** Nil.

**Conflict of Interest:** None declared.